

It is introduced commercially in 1962 by Bowen of the National Bureau of Standards most popular tooth colour material consist of a continuous polymeric or resin matrix in which an inorganic fillers is dispersed.

**Indications:**

1. Classes I, II, III, IV, V and VI restorations
2. Foundations or core buildups
3. Fissure sealants and conservative composite restorations (preventive resin restorations)
4. Esthetic enhancement procedures
  - Partial veneers
  - Full veneers
  - Tooth contour modifications
  - Diasthema closures
5. Cements (for indirect restorations)
6. Temporary restorations

**Contraindications:**

1. An operating area that cannot be adequately isolated.
2. Class V restorations that are not aesthetically critical.
3. Restorations that extend into the root surface (may exhibit gap formation).

**Advantages:**

1. Aesthetics
2. conservative of tooth structure removal (less extension; uniform depth not necessary; mechanical retention usually not necessary)
3. less complex when preparing the tooth
4. low thermal conductivity

5. bonded to tooth structure resulting in good retention, low micro leakage, minimal interfacial staining, and increased strength of remaining tooth structure
6. Repairable

### **Disadvantages**

1. may result to gap formation, usually occurring on root surfaces as a result of the forces of polymerization shrinkage of the composite material
2. restoration is more difficult, time-consuming, costly (compared to amalgam restorations)
3. Are more technique sensitive because the operating site must be appropriately isolated and the placement of etchant, primer, and adhesive on the tooth structure (enamel and dentin) is very demanding of proper technique
4. May exhibit greater occlusal wear in areas of high occlusal stress or when all of the tooth's occlusal contacts are on the composite material
5. Have a higher linear coefficient of thermal expansion, resulting in potential marginal percolation if an inadequate bonding technique is utilized

### **Composition**

A. Organic Resin – forms the matrix

-dimethacrylate monomer (BIS-GMA)

B. Inorganic filler

- inhibits deformation of the matrix

- reduce the coefficient of thermal expansion of the resin matrix

e.g. fused silica, crystalline quartz, lithium aluminum silicate, borosilicate glass

- better mechanical properties, such as compressive strength;

- greater aesthetics;

- confers radio-opacity

### C. Coupling Agent

- unite the resin with the filler
- stress absorber of the filler and resin

### D. Initiator System – activate the setting mechanism

### E. Stabilizers

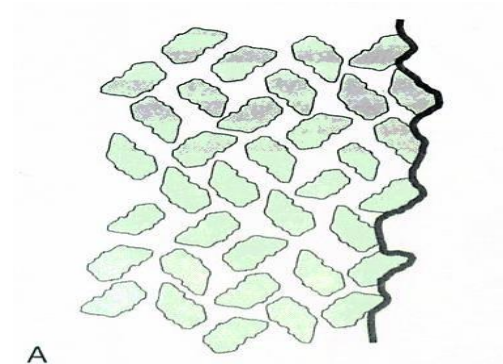
### F. Pigments

## Classification

1. Conventional
2. Microfilled
3. Hybrid -Flowable - Packable
4. Nano-composite (nanofilled) - Completely nanofilled - Nanohybrids
5. Reinforced

## Conventional Composites


1. contains 75-80% inorganic filler by weight
2. average particle size  $8\mu\text{m}$
3. large size particle and extremely hard filler
4. rough surface structure, strontium and barium glass (radiopaque)



## Microfilled Composites

1. introduced in the late 1970
2. polishable
3. smooth lustrous surface similar to tooth enamel
4. particle size is  $0.01 - 0.04\mu\text{m}$
5. contains 35-60% inorganic filler by weight

6. some of physical and mechanical properties are inferior; wear resistant
7. low modulus of elasticity (allow restoration to flex)
8. high resin content results in an increased coefficient of thermal expansion and lower strength

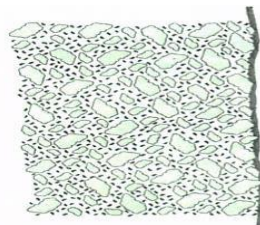


### **Use of Microfilled Composites**

- used for low stress restorations, buccal and lingual surfaces of class III and class V

### **Hybrid Composites**

1. combines the properties of conventional and microfilled
2. contains 75-85% inorganic filler by weight
3. particle size is 0.4 – 1 $\mu$ m
4. physical properties is superior to conventional
5. predominant direct aesthetic resin
6. have universal clinical applicability



### **Use of Hybrid Composites**

- used in moderate stress restorations where strength and wear resistance are more important than surface luster; Class I, class II, class IV

### **Flowable composites**

1. flows into cavity due to lower viscosity
2. have lower filler content
3. inferior physical properties (lower wear resistance, lower strength)

4. used in small class I, pit and fissure sealant, marginal repair materials, as the first increment placed as a liner under hybrid or packable composites
5. easy to use
6. good wet ability
7. favourable handling properties are popular features
8. clinical indications for their use are limited.

### **Packable (Condensable) composites**

1. more viscous, “thicker, stiffer feel”
2. have filler particle feature that prevents sliding of the filler particle by one another
3. easier restoration of proximal contact
4. similar to the handling of amalgam

### **Nanofill composites**

1. Contain filler particles that are extremely small (0.005-001 microm.)
2. Because of these small particles a high filler levels can be generated in the restorative material, resulting in good physical properties and esthetics
3. Nanofills highly polishable
4. These materials are likely to become a popular composite restorative material choice

### **Completely nanofilled resins**

Contain nano-meter sized particles throughout the resin particles

### **Nanohybrids resins**

Consist of large partials surrounded by nano-meter sized particles

### **Reinforced composites**

It consists of a combination of a resin matrix, randomly orientated E-glass fiber and inorganic particulate fillers.

**Used as** base filling material in high stress bearing areas especially in large cavities of vital and non- vital posterior teeth

### **Classification according to the method of activation:**

#### **1. Chemically-activated composites:**

Also they are called self -curing composite resins. Most commonly available as two-paste system composed of a catalyst and base materials. When these two components are property mixed, the polymerization process is chemically activated. The rate of set is uniform through the bulk of the material causing a gradual increase in viscosity at room temperature. Hence the material have a limited working time, making the technique time sensitive with the increased possibility of air bubble incorporation during mixing of the two pastes and thus affecting the composite physical and mechanical properties .

#### **2. Light-activated: composites:**

Light activated materials afford a number of advantages over chemically activated ones. The light curable materials are single components, and require no mixing, and so have reduced porosity, and better resistance to wear and abrasion. The working time is virtually that chosen by the clinicians, and the material hardens rapidly when exposed to light. The components of light -activated composites are contained in single paste system. The mixture is supplied in various shades in disposable syringes. These syringes are made of opaque plastic to protect the material from exposure to light.

#### **3. Dual cured composites:**

Combine self curing and light curing materials .The self curing rate is slow and is designed to cure only those portions that are not adequately light cured Specially in the interproximal areas where the access is limited and require special approaches to guarantee adequate light curing energy

## **1. Ultraviolet light source:**

The introduction of photopolymerization to dentistry began in the late 1960s. Initially, ultraviolet cured pit and fissure sealant were put into clinical practice, UV radiation cause possible eye problems that might develop in office personnel and the possibility of selectively altering the oral flora of the patient's mouth through exposure to ionizing radiation.

## **2. Visible light sources:**

### **A- Quartz-Tungsten-halogen (QTH) light source:**

A modified light source delivery was introduced in the form of the handheld dental curing light.

Visible radiation passed through the infrared filter, is then further filtered by a band pass filter, providing energy restricted to a narrow visible light region where the absorbance of the photoinitiator is maximum, so that, only blue light is emitted. However, only the wavelengths around 470 nm are strongly absorbed by the Composite.

### **B- Argon laser lights**

When laser technology provided sources that emitted high-intensity light within the energy band required by the photoinitiator in light-activated dental materials, the dental industry developed this type of curing source for the practitioner. The argon-ion laser provides high output energy at 488 nm for rapid polymerization of commercially available dental restorative

### **C. Short-Arc Xenon Sources (Plasma-Arc Curing lights (PAC)):**

In the mid 1990s, Xenon arc light units were introduced in restorative dentistry as alternative for rapid light curing. Manufacturers claimed that these sources can effectively reduce clinical exposure duration to only 1 to 10-seconds or some manufacturers claimed that composites could be adequately polymerized in less than 1 second.

## **D. Blue light- emitting diode curing units (LED) s**

The blue LED has become available in output wavelengths that fall within the spectral absorbance of a common dental photoinitiator (CQ). The intensity of these devices has increased at a rapid rate, and now commercial devices are available for the photopolymerization of dental composites. Instead of the hot filaments used in halogen bulbs, LED, use junction of doped semiconductors for generation light.

### **Polymerization:**

Resin composite restoratives solidify by means of the chemical process termed polymerization. The polymerization of the resin matrix produces a gelation in which the restorative material is transformed from a viscous-plastic into a rigid-elastic phase. During the early stages of polymerization, monomers are mainly converted into polymeric chains.

After a certain degree of conversion has been attained, the predominant reaction is the cross-linking of the polymeric chains, resulting in a strong polymeric network.

## **Factors affecting polymerization shrinkage stress:**

### **1-Factors related to the cavity design:**

Stress developed during curing can be minimized by consideration of the ratio between the bonded and unbonded surface area (c- factor). When this ratio increases, as in Class I and Class V situations, increase the shrinkage stress loading on the tooth- resin interface leading to de bonding.

### **2-Factors related to the placement technique:**

The second factor that might reduce polymerization shrinkage is to insert resin composites in increments to reduce the volume of the resin that is shrinking during polymerization.

### **3-Factors related to the composite formulation:**

Nonbonded microfiller particles have been found to produce significant decreases in polymerization stress by acting as stress-relieving sites within the composite.

#### **Acid Etching:**

- A physical process that creates a microscopically rough enamel surface (enamel tags)
- first successful technique developed to bond dental materials to tooth structure
- acid used is 37% ortho-phosphoric acid
- sometimes referred to as conditioner

**Smear Layer:** When a rotary or handheld instrument is used on dentin it creates a special surface texture called a smear or smear layer that closes off the dentinal tubules. This layer is lightly adhered to the dentin surface and contains tooth cuttings, saliva, bacteria, and other surface debris

#### **Enamel Etching**

Enamel consists of organic and inorganic components. Application of 37% phosphoric acid removes about 10 microns of enamel to expose prisms of enamel rods and create the classic honeycomb effect. Acid also increases surface energy for better wetting of the enamel. Resins flow into micromechanical retentive areas. Resin tags fill microscopic holes to provide retention. Retention is about 30 MPa.

Acid etching is done for a minimum of 15 to 30 seconds. Thorough rinsing for 10 seconds removes acid and dissolved calcium phosphates.

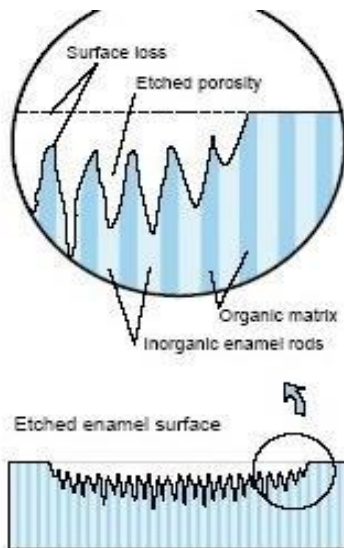


Figure 8-3. Schematic diagram depicting how acid etching produces microporosities in enamel.

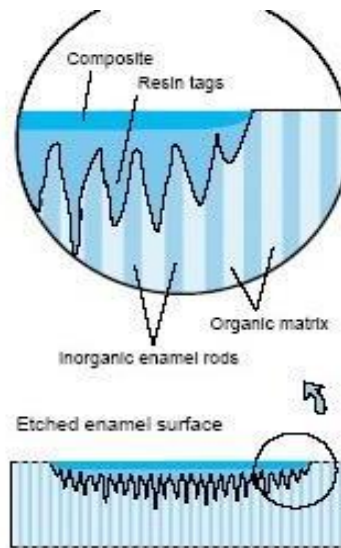


Figure 8-4. Schematic diagram depicting how resin tags penetrate the microporosities produced by acid etching of enamel.

- Over-etching results to formation of crystals (precipitates) that inhibits bonding
- Built-in quality control check – if properly etched it appears frosty or chalky white.

### Dentin Etching

- 37% ortho-phosphoric acid
- removes the smear layer from the surface of the of the dentin as well as the plugs of material forces into dentinal tubules during cavity preparation.
- decalcifies a layer of dentin several microns thick. Time: 10-15 seconds

If the etched tooth surfaces are contaminated with saliva or blood, they need to be reetched. Such a reetching procedure requires only 5 seconds.

### Adhesion to Dentin

**Conditioning or Etchant (E):-** dentin etching time 15 sec only

- Removes the smear layer.
- Exposes the intertubular and peritubular collagen.
- Opens the tubules.
- Decreases the surface free energy.

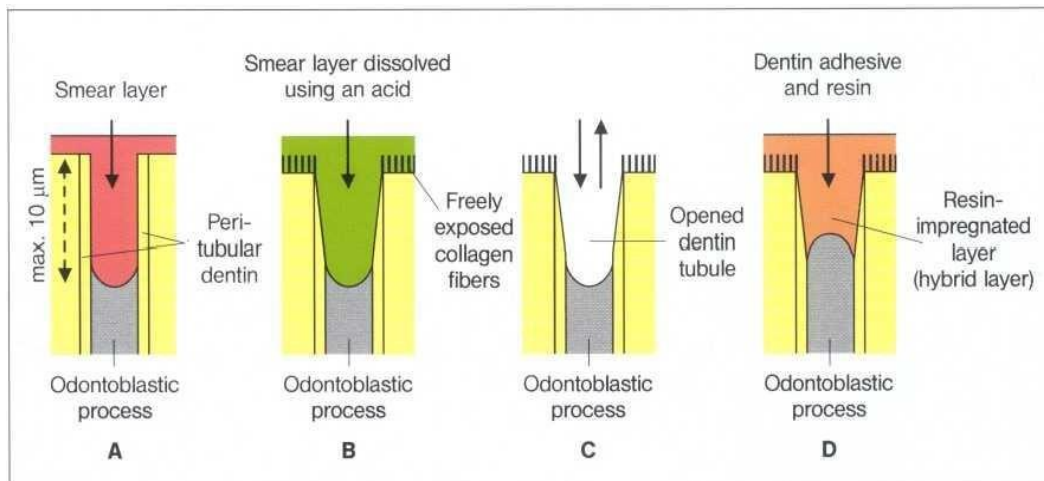
### Primer (P):-

- Includes bifunctional molecules hydrophilic and hydrophobic).
- Envelops the external surface of collagen fibrils.
- Re-establishes surface free energy to levels compatible with more hydrophobic restorative materials

### Bonding Agent (B): (Adhesive resin)

- Includes monomers that are mostly hydrophobic such as Bis-GMA
- Copolymerize with the primer molecules penetrates and polymerizes into interfibrillar spaces to serve as a structural backbone to hybrid layer.

**Adhesion to Dentin** protects the pulp, because after removal of the smear layer with a mild acid (conditioner) the opened dentin wound was sealed with a hydrophilic resin, for example, HEMA (primer) and a bonding agent (adhesive). During this treatment a dentin surface impregnated with resin (hybrid layer) is formed that guarantees an optimal dentin wound closure which is acid resistant and prevents bacteria penetrating.



Effect of the total etch technique on the opening of the dentin canals

A- Prepared cavity

B -The smear layer is dissolved through treatment with phosphoric acid

C- The acid and the dissolved smear layer are washed away using a water-air spray

D- Forming the hybrid layer with a dentin adhesive

## **Current strategies for Adhesion of Resin to Dentin:**

### **I-Total etch adhesive**

#### **A- Three step total etch adhesive:**

Etchant (E) + Primer (P) + Bonding Agent (B)

#### **B- One-bottle total –etch (two step total-etch adhesive):**

Etchant (E) +Primer and Bonding agent (PB)

### **II-Self-etch adhesive:**

#### **A- Two –bottle self-etch:**

Etchant and Primer (EP) + Bonding (B)

#### **B- All-in-one self-etch (EPB) we call it single application:**

-it demineralises and penetrates dentin simultaneously leaving a precipitate on the hybrid layer.

- Forms a thin layer of adhesive.
- a multi-coat approach is recommended.

### **Adhesive strategies – principles:**

- 1- Acid etch will remove smear layer with collagen fibers upright, tubules open, primer and adhesive penetrate.
- 2- Leave smear intact, tubules plugged, partially demineralize smear layer with self- etching primer and replaced with resin filler in to tubuler dentin.

## **CAVITY PREPARATION FOR COMPOSITE RESTORATIONS**

Three designs of tooth preparations for composite restorations, and sometimes they are used in combination. The designs include:

- (1) Conventional      (2) Beveled conventional      (3) Modified

### **Class III Tooth Preparation:**

There is a choice between facial or lingual entry into the tooth

#### **Indications for Lingual Approach**

- 1- To conserve facial enamel for enhanced esthetics.
- 2- Carious lesion is positioned lingually.

- 3- Lesion is accessible from the lingual.
- 4- Color matching of the composite is not as critical.
- 5- Discoloration or deterioration of the restoration is less visible.

### **Indications for Facial Approach**

- 1- The carious lesion is positioned facially
- 2- Teeth are irregularly aligned, making lingual access undesirable.
- 3- Extensive caries extent into the facial surface.
- 4- Faulty restoration that was originally placed at the facial.

### **Conventional Class III**

Indicated for restorations involving the root surface

1. Using a No. ½, 1, 2 round bur prepare the outline form on the root surface
2. Extend the preparation into sound walls
3. Extend pulpally 0.75mm in depth
4. The gingival/cervical and incisal wall is perpendicular to the root surface (box like design)
5. A continuous groove retention can be prepared 0.25 mm (½ of diameter of bur) into dentin of the gingival and incisal walls with a ¼ round bur.
6. The groove is placed at the junction of the axial and the external walls.
7. Clean preparation and inspect the final preparation.

### **Bevelled Conventional Class III**

- Indicated for replacing an existing defective restoration in the crown portion of the tooth
- When restoring a large carious lesion for which the need for increased retention and/or resistance form is anticipated.

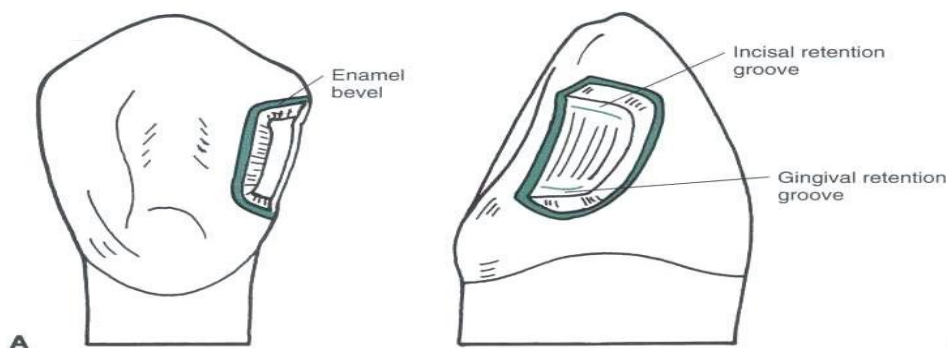
### **Lingual Access**

1. Use a round bur No. 1/2, 1, 2 depending on the size of the caries to enlarge the opening sufficiently to allow for caries removal.
2. Extend external walls to sound tooth structure using a straight bur

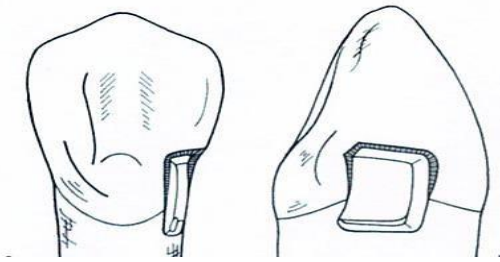
3. Extend the gingival and incisal walls up to extent of caries or location of old restoration.

Unless necessary, DO NOT:

- include the proximal contact.
  - extend into the facial surface.
  - extend subgingivally
4. Create an initial axial wall depth of 0.2mm into the dentin/DEJ (approximately 0.75 – 1.25mm in depth)
  5. Axial wall is convex, following the external contour of the tooth.
  6. Remove all remaining infected dentin, using a round bur or small spoon excavator.
  7. Remove friable enamel at the margins.
  8. If necessary, prepare retention (grooves or coves)
    - prepare it along the gingivoxial line angle, and sometimes at the incisioaxial line angle 0.25 mm with a ¼ round bur.



9. Place cavosurface bevel or flare at the enamel except at the gingival margin area.
10. Use a flame shape or round bur resulting in a 45 degrees angle to the external tooth surface.
11. Bevel width should be 0.25 to 0.5mm.
12. Clean the preparation of any debris and inspect final preparation.

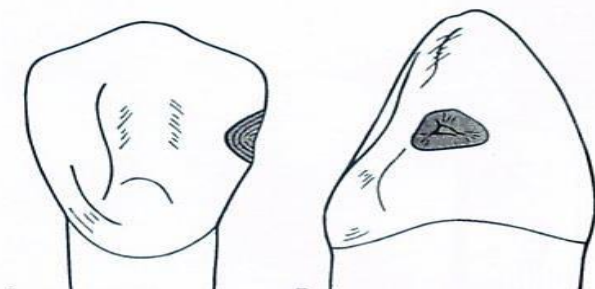


### Facial Access

- same stages and steps are followed
- procedure is simplified because of easy access

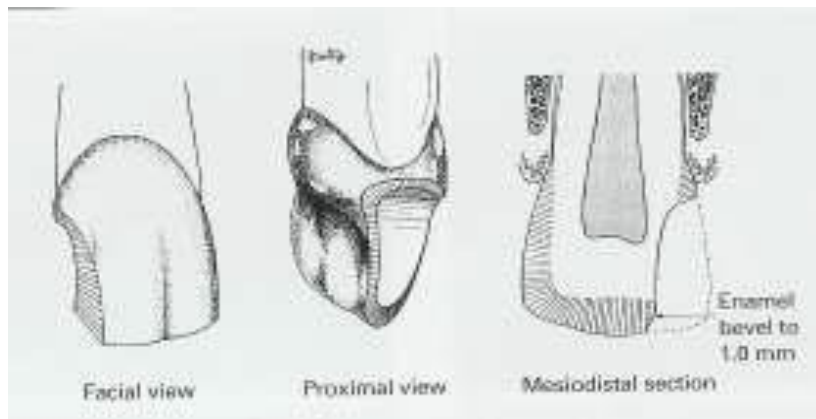
### Modified Class III

- most used type of cavity preparation.
  - indicated for small and moderate lesions or faults.
  - designed to be as conservative as possible.
  - preparation walls have no specific shapes or forms.
  - preparation design appears to be scooped or concave
1. Use a 1/2, 1, 2 round bur, point of entry is within the incisogingival dimension of the lesion, perpendicular to the enamel surface.
  2. Remove all remaining caries or defect.



3. No attempt is made to create a uniform axial wall.
4. Place cavosurface bevel or flare at the enamel except at the gingival margin area.
5. Use a flame shape or round bur resulting in a 45 degrees angle to the external tooth surface.
6. Bevel width should be 0.25 to 0.5mm.
7. Clean the preparation of any debris and inspect final preparation.

## Class IV Tooth Preparation



- preoperative assessment of occlusion is very important (placement of margin in noncontact areas)
- shade selection is more difficult
- preparation is similar to Class III except that the preparation for class IV is extended to the incisal angles

For fracture: If no caries or pulpal involvement a bevel is the only preparation necessary 1.0-2 mm enamel bevel should be placed around the periphery of the cavity

Use of Pins:

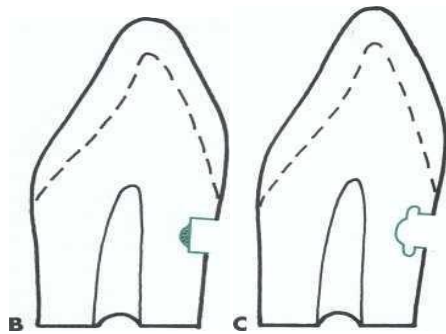
\* Retentive pins are not needed because the adhesive technique provides sufficient retention for the restoration

## Class V Tooth Preparation

### Conventional

- the feature of the preparation include a 90 degree cavosurface angle, uniform depth of the axial line angle, and sometimes, groove retention form.
  - conventional design is indicated only for portion of the lesion extended onto the root surface
1. Use a tapered fissure (No. 700, 701, or 271) or No.1 or 2 round bur.
  2. Make entry at 45 degrees angle to tooth surface, this should result to a 90 degree cavosurface.

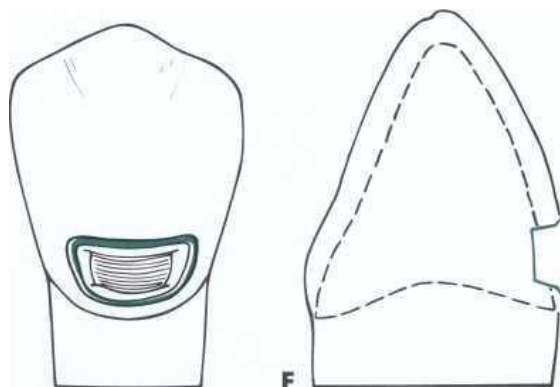
3. Axial depth is 0.75 mm to strength of preparation wall, strength of composite and placement of retention groove
4. Axial should follow contour of the tooth.
5. Extent of outline form is dictated by the carious lesion extent.
6. Remove remaining carious lesion
7. Prepare retention groove (similar to Class III preparation)
8. Clean preparation



### Bevelled Conventional Class V

- Indications

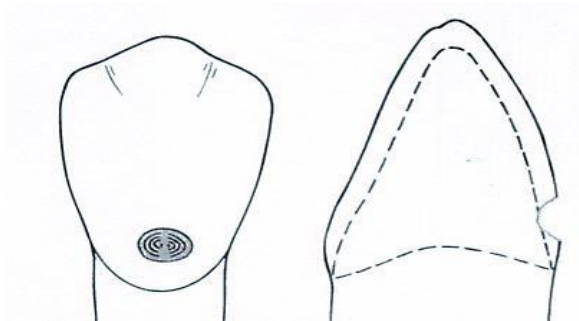
1. replacement of defective class V restorations
2. large carious lesion
  - exhibits 90 degrees of cavosurface
  - axial wall depth is uniform (0.2mm or 0.5 when retention groove is to placed)



- groove is not indicated when periphery of tooth preparation is located in enamel.
- remove all infected dentin
- clean preparation

## Modified Class V

- indicated for small and moderate lesion and lesion entirely in the enamel
- no effort to prepare a butt-joint
- no retention groove
- lesion is scooped out
- preparation has divergent wall
- axial wall does not have uniform depth
- prepare tooth with round or elliptical instrument
- preparation is extended initially no deeper than 0.2 mm
- no effort is made to prepare a 90 degree cavosurface margins.
- infected enamel is removed with a round bur or excavator.



### Restorative Technique

1. Determine shade of tooth

### Shade Selection:

After caries removal and cavity preparation shade selection was done using shade guide

### Restorative Technique

1. Determine shade of tooth
2. Clean the tooth preparation using slurry of pumice, polishing cup.
3. Isolate the tooth, preferably with a rubber dam or cotton rolls, to keep the prepared teeth from saliva, blood, debris and other fluids..
4. Protect adjacent unprepared tooth from the acid etchant with a polyester strip apply the wedge.
5. Apply the gel etchant 0.5 beyond the prepared margins onto the adjacent unprepared tooth.
6. Etchant is left undisturbed for 15 seconds.
7. The area is washed to remove the etchant.

8. Dry the tooth structure
9. Bonding system is applied on all tooth structure that has been etched with a microbrush or other suitable applicators
- 10-Application of Bonding Agent: Application of the bonding agent and then cured for 10 seconds.
11. Incrementally place composite material and cure.
12. **Curing of the Composite:** The material is cured using the light curing machine for 20 seconds for every increment of composite that was placed.
13. **Finishing and Polishing:** The use of polishers with enhancers and polishing paste were done after the trimming of the excess composites.